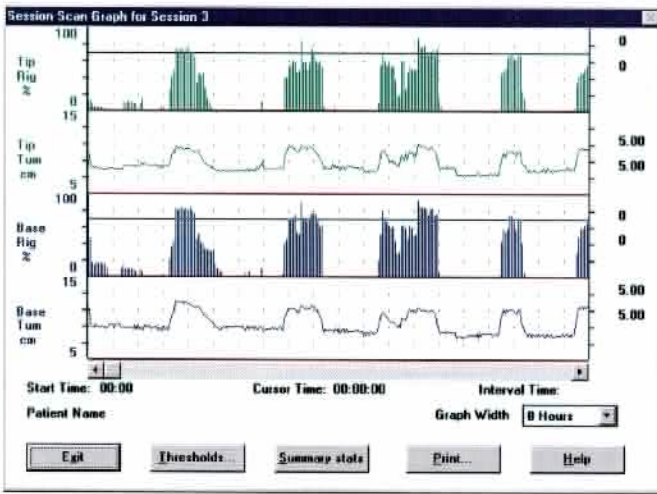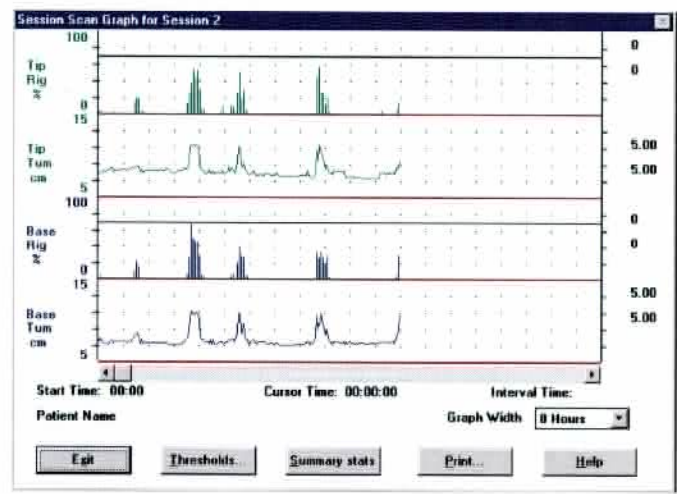


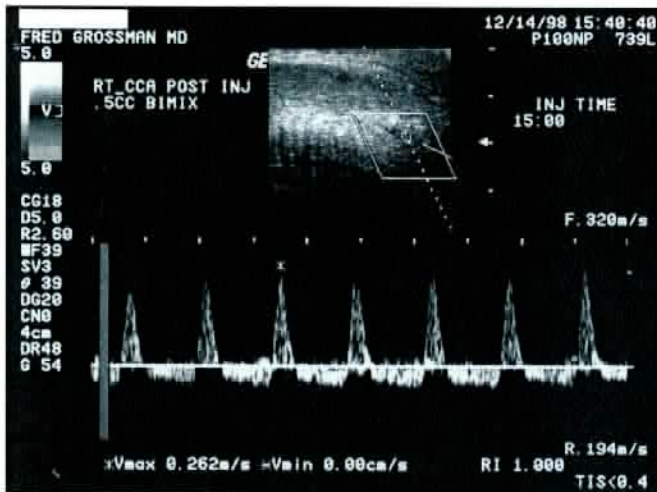### NPT Example 1

Normal at home eight hour nocturnal penile tumescence study. No sign of organic impotence.



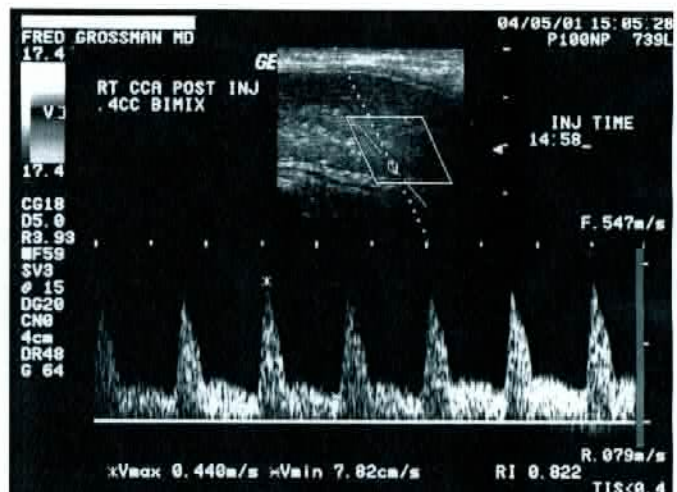
### NPT Example 2

Six hour home NPT study showing inadequate erections but good frequency of events. This is suggestive of organic (non-psychogenic) impotence.



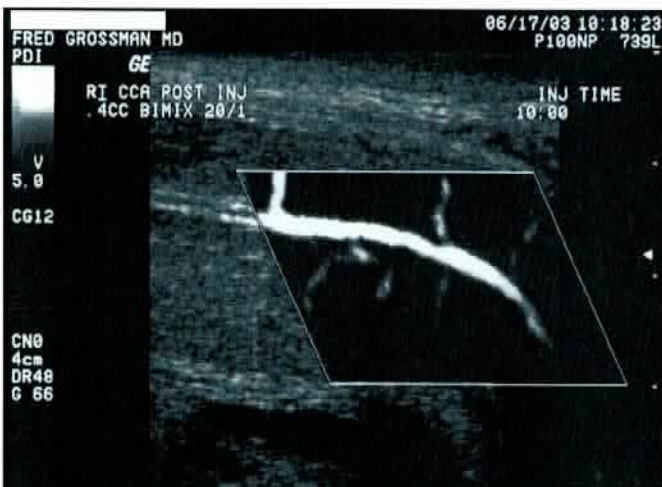
### Penile Doppler, Arterial Insufficiency

Cavernosal artery with inadequate flow 40 minutes after induction of erection – arteriogenic impotence.



### Penile Doppler, Venous Leak

Cavernosal artery after erection induction showing abnormal continued flow between systole – venogenic or venous leak impotence.



Ultrasonic image of normal right penile cavernosal artery.

Fred Grossman, M.D.

Adult Urology and Impotence



Certified American Board of Urology  
Fellow, American College of Surgeons

Phone: 303-571-1355

Fax: 303-571-1520

www.malecarecenter.com